

Automated identification of Intima Media Thickness in Ultrasound Artery Images

Author: M.Sulochana¹; S.Antony Mutharasan²

Affiliation: PG Scholar¹; Assistant Professor²

Department of Computer Science and Engineering

Sardar Raja College of Engineering, Tamilnadu, India

Abstract- In this paper presents identification of intima media thickness (IMT) in common carotid Artery ultrasound video sequence. It is fully using automatic segmentation, these are based on unsupervised manner. The aim of this study introduces a novel unsupervised Computer Aided Detection (CAD) Algorithm that is able to identify and measure the IMT in 2D ultrasound carotid images. The developed technique relies on a suite on image processing algorithms that embeds a statistical model to identify the two interfaces that form the IMT without user intervention. The experimental results show that the proposed CAD system is robust in accurately estimating the IMT in ultrasound carotid data.

Keywords- Edge detection, Common Carotid Artery, Ultrasound, Intima Media Thickness, Lumen Intima, Media Adventitia, Segmentation.

1. INTRODUCTION

Common carotid intima media wall thicknesses is a reliable measure of atherosclerosis, myocardial infarction and stroke, are responsible for approximately 35% of total mortality in the western world, and are leading causes of morbidity burden world-wide. The first indication of atherosclerotic vascular disease is a thickening of the intimal and medial layers of the arterial wall. The goal of this paper was introduce an efficient Computer Aided Detection Algorithm for the segmentation of IMT in 2D ultrasound Artery Images. It can easily identify the IMT in order to detect early abnormalities in the carotid artery images. Carotid intima media thickness (IMT) is a measure of early atherosclerosis which can be evaluated non-invasively and with low cost, using high-resolution ultrasound (US). It is the distance between the lumen-intima and the media-adventitia interfaces; and can be seen in US as the double line pattern on both walls of the longitudinal images of the common carotid artery (CCA). Carotid IMT is correlated with all traditional vascular risk factors and regarded as an

intermediate phenotype of atherosclerosis or a marker of subclinical organ damage and has been shown to positively correlate with the severity of atherosclerosis and independently predict cardiovascular events [3]. Thus, the IMT may be used for the screening of population as at least half of premature heart attacks and strokes, can, and should, be prevented. IMT can be measured through segmentation of the intima media complex (IMC), which corresponds to the intima and media layers (see Fig. 1) of the arterial wall. Determination of the IMC boundaries is however a complicated task, as the IMC is a thin, relatively low contrast structure, that can be obstructed by ultrasound artifacts, may appear differently due to either different imaging angles and/or differences in anatomy and deteriorates with age [4].

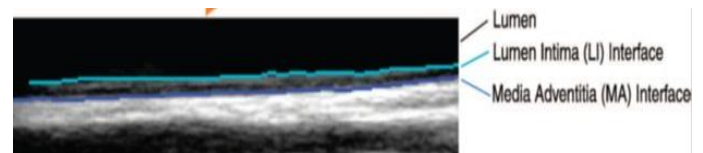


Figure 1; lumen-intima (LI) and media-adventitia (MA) Interfaces.

There is a number of techniques that have been proposed for the segmentation of the IMC [5], [6], [7], [8], [9], however most of them are semi-automatic and need user intervention. Pignoli and Longo [5] were the first to tackle the evaluation of the IMT using the intensity outline from the center of the lumen to the corresponding borders. Selzer et al. [10] presented a tracking edge method, where the user uses a mouse to identify a few points along the intima and media boundaries. The algorithm fits a smooth curve through these points and uses it as a guide for edge detection, searching in the vicinity of this curve evaluating intensity gradients. Adaptive Normalized Correlation Algorithm for tracking the subsequent frame Liang et al. [6] used dynamic programming incorporating multiple image features at different scales for a fuzzy membership function. In case of ambiguous cases the user can intervene. Cheng et al. [8]

proposed a method using active contours for the evaluation of the IMT. Their algorithm needs an initialization where the user locates points near the intima-lumen boundary. Stein et al. [9] presented a method where after the user identified a position in the lumen the algorithm evaluated the IMT using intensity and gradient information combined with morphological smoothing. Loizou et al. [2] presented a semi-automatic method for IMC segmentation.

2. METHOD

The Developed CAD system relies on a suite of image processing algorithm that embeds statistical model to identify the two interfaces such as lumen intima and media adventia that form the IMT complex without any user intervention. The proposed IMT segmentation scheme is based on a spatially continuous vascular model and consists of several steps in the following sub sections of this paper. An outline of the proposed method illustrated in Fig.2

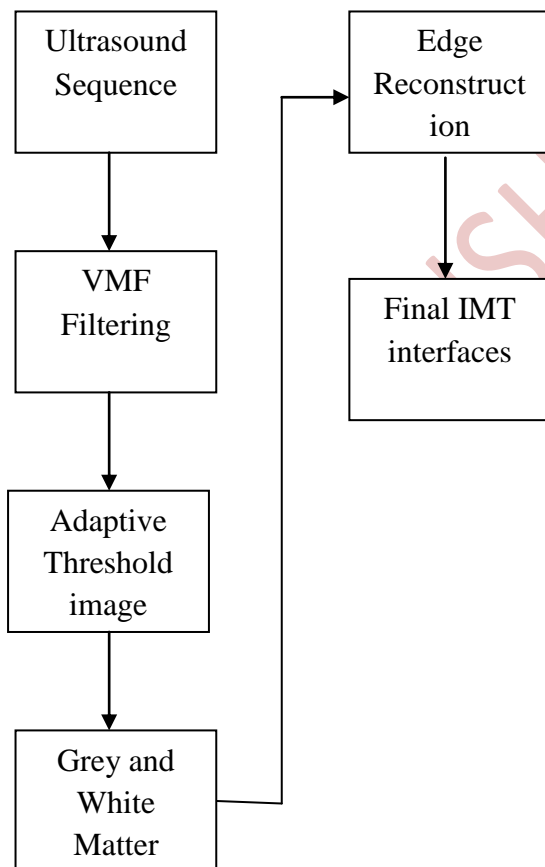


Figure 2: Block diagram of Segmentation

2.1. Automatic Detection of the Region of Interest (ROI)

Automatic detection of region of interest (ROIs) in a complex image or video, such as an angiogram or endoscopic neurosurgery video, is a critical task in many medical image and video processing applications. The main principle behind the proposed approach is to identify the location of the far wall interface using a suite of image processing steps that combine the information contained in the intensity domain with knowledge relating to the anatomical structure of the carotid artery. Because the variation of the intensity values in B-mode carotid ultrasound images can be approximated with a bimodal distribution. Thus, prior to VMF filtering, the extraction of linear scaling filter that utilizes local mean and variance, as in [15], is applied to despeckle the image.

The proposed algorithm starts with an adaptive thresholding algorithm that is applied to detect the borders between the two main image classes: the blood and the arterial tissues. The thresholding operation results in a binary image where the blood and artery tissue classes are formed based on 0 and 255. The value 0 represent the blood class and value 255 represent the arterial tissue. The thresholding operation results in a binary image where the blood and artery tissue classes are formed:

$$\begin{aligned}
 \text{If } I(x, y) \leq k &\Rightarrow I(x, y) = 0(\text{bloodclass}) \\
 \text{If } I(x, y) > k &\Rightarrow I(x, y) = 255(\text{tissueclass})
 \end{aligned}
 \tag{1}$$

Where $I(x, y)$ denotes the intensity value of the input image at location (x, y) . In this approach, the threshold k is automatically detected by maximizing the between class variance.



Figure 3: ROI detection: blood (in black) and the arterial tissue (in gray).

To filter the ROI, through the image with a square mask of size $w \times w$ centered at every pixel in the ROI. Using VMF, every pixel under analysis will be replaced with the pixel from its neighborhood $w \times w$ that returns the minimum Euclidian distance to all other pixels in the neighborhood as follows,

$$I_{ROI}(P_{min}, Q_{min}) = \min_{(p,q) \in w \times w} \sum_{(u,v) \in w \times w} \|I_{ROI}(u,v) - I_{ROI}(p,q)\| \quad (2)$$

$$I_{ROI}(x, y) \leftarrow I_{ROI}(P_{min}, Q_{min})$$

In equation (2), (p_{min}, q_{min}) are the coordinates of the pixel that returns the minimum distance to all pixels located within the mask $w \times w$. To attain feature preservation, the VMF should be applied in a small neighborhood to prevent the edge attenuation that occurs when the VMF filtering scheme is applied for large neighborhoods. In the implementation the neighborhood $w \times w$ is set to 3×3 .

2.2. Global Contrast Enhancement

The low contrast between the anatomical structures is one of the main drawbacks associated with the ultrasound imaging modality. Due to low echo responses caused by the ultrasound acquisition process, certain sections of the IMT have a reduced contrast and are not easily distinguishable. In order to improve the appearance of the IMT and facilitate its detection, a

global contrast enhancement based on data stretching between two pre-defined thresholds c_{min} and c_{max} , was applied:

$$I_{ce}(x, y) = \frac{255 [I(x, y) - c_{min}]}{c_{max} - c_{min}} \quad (3)$$

where $I(x,y)$ is the intensity value of the pixel situated at position (x,y) in the image matrix and $I_{ce}(x,y)$ is the contrast enhanced intensity value. Based on experimentation the values of c_{min} and c_{max} are set to 6 and 150 respectively and are kept constant for all images analyzed in this study. The selection of these two thresholds proved to be robust irrespective of the ultrasound equipment that has been employed to capture the image data.

2.3. Segmentation Using Canny edge detection Without Edges and Image Normalization

A fully automated IMC segmentation algorithm needs to be able to work on all images despite variability due to capture time, settings and scanners. Normalization of B- mode US images for the CCA has been shown to address this variability using intensity adjustments that take into account anatomy and differences in tissue attenuation. The normalization method proposed in [15] performs linear grayscale remapping so that median intensity value of the artery lumen has intensities between 0 and 5, and the median intensity value of the adventitia between 180 and 190 for 8 bit US images [16]. The normalization reduces image variability due to the reasons aforementioned. However, the normalization requires human interaction for choosing a region in the lumen and another in the adventitia so that corresponding intensity values are established for the intensity remapping. Automation of the image normalization can be achieved with the use of the level set formulation of the canny edge without edges [13]. The edge can be detected using Canny edge detection method [20]. The IMC segmentation process involves the extraction of the plausible initial coarse edge segments that are associated with the Media Adventitia and Lumen Intima interfaces by applying the canny edge detector to the image data sampled by the ROI.

3. EVALUATION OF THE PROPOSED ALGORITHM

All 49 images contained in database have been manually annotated by clinical experts from Beaumont Hospital. The accuracy of the algorithm is determined by computing the minimum Euclidian distance between the pixels situated on the border of the lumen-intima interface and media-adventitia

interface in the ground truth image and the pixels from the lumen-intima interface and media adventitia interface identified by the proposed algorithm. To evaluate the border displacement between the ground truth annotated data and the segmented IMT, the mean, standard deviation and Root Mean Square errors were calculated. The evaluation was performed separately for both interfaces that form the IMT. The overall numerical results (calculated both in pixels and in mm). The numerical results indicate that no significant differences between the ground truth IMT and the segmented IMT occur.

4. CONCLUSION

This paper presents a fully automated method for the segmentation of the IMC so that the IMT can be evaluated. The main novelty of this approach resides in the development of an unsupervised algorithm that embeds a statistical IMT model in a coarse to fine fashion. The algorithm works well even on difficult cases, but further evaluation is required. The proposed CAD system to automatically measure the IMT in multidimensional (2D+time) ultrasound carotid data in order to allow the calculation of dynamical properties of the carotid artery. Future work will involve assessment of the algorithm on a much larger dataset and discussion of how inter- and intra- observer variability affects the evaluation of the results.

5. REFERENCES

- [1] C. Loizou, C. Pattichis, M. Pantziaris, T. Tyllis, and A. Nicolaides "Snakes based segmentation of the common carotid artery intim media," *Medical and Biological Engineering and Computing*, vol. 45 pp. 35-49, 2007.
- [2] C. Loizou, C. Pattichis, M. Pantziaris, T. Tyllis, and A. Nicolaides, "Quality evaluation of ultrasound imaging in the carotid artery based on normalization and speckle reduction filtering," *Medical and Biological Engineering and Computing*, vol. 44, pp. 414-426, 2006.
- [3] D. Cheng, A. Schmidt, K. Cheng, and H. Burkhardt, "Using snake to detect the intimal and adventitial layers of the common carotid artery wall in sonographic images," *Computer Methods and Program in Biomedicine*, vol. 67, no. 1, pp. 27 - 37, 2002.
- [4] D.E Ilea, P.F Whelan, C.Brown and A.Stanton "Automatic detection and measurement of the IMT in longitudinal sections of the ultrasound images of the CCA" in *European Congress of Radiology (ECR)*, 2010, art.no.SS 1205, B-522.
- [5] D. J. Williams and M. Shah, "A fast algorithm for active contours and curvature estimation," *International Journal on Graphics, Vision and Image Processing: Image Understanding*, vol. 55, pp. 14 - 26, 1992.
- [6] D. Mumford and J. Shah, "Optimal approximation by piecewise smooth functions and associated variational problems," *Communi- cation of Pure and Applied*
- [7] D. Lamont, L. Parker, M. White, N. Unwin, S. M. A. Bennet M. Cohen, D. Richardson, H. O. Dickinson, A. Adamson, K. G. M Alberti, and A. W. Craft, "Risk of cardiovascular disease measured b carotid intima-media thickness at age 49-51: lifecourse study," *Britis Medical Journal*, vol. 320, no. 7230, pp. 273-278, 2000. *Mathematics*, vol. 42, pp. 577-685, 1989.
- [8] F. Molinari, G. Zeng, and J. S. Suri, "A state of the art review on intima-media thickness measurement and wall segmentation techniques for carotid ultrasound," *Computer Methods and Programs in Biomedicine*, vol. 100, pp. 201 - 221, 2010.
- [9] I. Wendelhag, Q. Liang, T. Gustavsson, and J. Wikstrand, "A new automated computerized analyzing system simplifies readings and reduces the variability in ultrasound measurement of intima-media thickness," *Stroke*, vol. 28, no. 11, pp. 2195-2200, 1997.
- [10] J.Canny "A computational Approach to edge detection" *IEEE Transaction on pattern Analysis and Machine Intelligence* vol.8, no.6, pp679-698, 1986.
- [11] M. Kass, A. Witkin, and D. Terzopoulos, "Snakes: Active contour models," *International Journal of Computer Vision*, vol. 1, pp. 321- 331, 1988.
- [12] M. W. Lorenz, H. S. Markus, M. L. Bots, M. Rosvall, and M. Sitzer "Prediction of clinical cardiovascular events with carotid intima-medi thickness: A systematic review and meta-analysis," *Circulation*, vol 115, no. 4, pp. 459-467, 2007.
- [13] P. Touboul, M. Hennerici, S. Meairs, H. Adams, P. Amarenco N. Bornstein, L. Csiba, M. Desvarieux, S. Ebrahim, and et al "Mannheim carotid intima-media thickness consensus (2004-2006)," *Cerebrovascular Diseases*, vol. 23, pp. 75-80, 2007.
- [14] P. Pignoli and T. Longo, "Evaluation of atherosclerosis with b-mode ultrasound imaging," *Journal of Nuclear Medicine and Allied Sciences* vol. 32, pp. 166-173, 1988.
- [15] Q. Liang, I. Wendelhag, J. Wikstrand, and T. Gustavsson, "A Multiscale Programming Dynamic Procedure boundary detection in ultrasound Artery images," *Medical Imaging, IEEE Transactions on* vol. 19, no. 2, pp. 127 -142, 2000.
- [16] R. H. Selzer, W. J. Mack, P. L. Lee, H. Kwong-Fu, and H. N. Hodis "Improved common carotid elasticity and intima-media thickness measurements from computer analysis of sequential ultrasound frames," *Atherosclerosis*, vol. 154, no.

- 1, pp. 185 – 193, 2001.
- [17] R. H. Selzer, H. N. Hodis, H. Kwong-Fu, W. J. Mack, P. Lee, C. ran Liu, and C. hua Liu, "Evaluation of computerized edge tracking for quantifying intima-media thickness of the common carotid artery from b-mode ultrasound images," *Atherosclerosis*, vol. 111, no. 1, pp. 1 – 11, 1994.
- [18] S. Osher and J. A. Sethian, "Fronts propagating with curvature dependent speed: algorithms based on hamilton-jacobi formulations," *Journal of Computational Physics*, vol. 79, pp. 12–49, 1988.
- [19] T. Chan and L. Vese, "Active contours without edges," *IEEE Transactions on Image Processing*, vol. 10, pp. 266 –277, 2001.
- [20] T. J. Tegos, M. M. Sabetai, A. N. Nicolaides, T. S. Elatrozy, S. Dhanjil, and J. M. Stevens, "Patterns of brain computed tomography infarction and carotid plaque echogenicity," *Journal of Vascular Surgery*, vol. 33, no. 2, pp. 334 – 339, 2001.

IJSHRE